Biochem. Cell. Arch. Vol. 18, No. 1, pp. 557-560, 2018 | www.connectjournals.com/bca | *ISSN 0972-5075*

WEBER'S SALIVARY GLANDS OF RABBIT : HISTOLOGICAL AND HISTOCHEMICAL STUDIES

Kahdem M. Haddao and Akram Y. Yasear

Department of Basic Medical Sciences, College of Dentistry, University of Kerbala, Kerbala, Iraq.
e-mail: kademhaddoo@yahoo.com, ykram @yahoo.com

(Accepted 22 January 2018)

ABSTRACT : Weber's glands are part of lingual minor salivary glands in the root of the tongue in rabbitand other mammals. Twenty six male rabbits were used in this work. Roots of tongues were excised out from anesthetized young rabbits, and fixed in neutral buffered formalin to be processed for light microscopy. Sections stained by Haematoxylin and Eosin, Masson's trichrome, and with special stains for carbohydrate histochemistry (PAS, alcian blue -AB-) pH 1.0, pH2.5, and AB pH 2.5/ PAS combination). Weber's glands in rabbit were mixed glands, but predominantly mucous. There were serous demilunes capping mucous tubules together with small number of serous acini. The serous cells contained neutral mucouosubstances, while the mucous cells displayed acidic mucouosubstances. The gland constitutes part of mucous salivary ring which is guarding the oropharynx to facilitate the swallowing of the food. The serous secretion from these glands support the function of nonlingual taste buds in the area of oropharynx.

Key words : Rabbit, lingual minor salivary glands, mucous cells, histological features.

INTRODUCTION

Weber's glands are a group of minor salivary glands located in the root of the tongue (Enni *et al*, 2017). They are part of the salivary mucous ring which aid in swallowing of the food (Rival *et al*, 1999; Avery, 2002). They were dissected out and discovered in 1827 by Weber. Early light microscopic studies (Zimermman, 1927) suggested that these structures were pure mucous glands. Mammalian Weber's glands were a subject of research interest by many investigators. In rat (Nagato *et al*, 1997; Ren, 1999) and Opossums (Okada *et al*, 2013). They are mixed glands rather being mucous as in man (Tandler and Riva, 1986; Berkovitz *et al*, 2003; Nanci, 2003; Smith and Pinkstaff, 1982). Weber's glands in the lesser bushbaby (Smith and Pinkstaff, 1982) and members of the rodentia (Nogieria and Carvalho, 1973) (rat, mouse, hamster, guinea pig) were reported to contain neutral glycoconjugate and sialomucins. In human beings, (Berkovitz *et al*, 2003) the ducts of Weber's glands open into the crypts of lingual tonsils.

The present work was aimed to describe the histology and mucosubstances histochemistry, in order to correlate the histological features of the secretory units with functions ascribed to them as part of mucous salivary ring, which helps in swallowing of the food.

MATERIALS AND METHODS

Twenty six young male rabbits were selected for this work. The roots of their tongue were sampled to be immersed immediately in neutral buffered formalin for fixation. The specimens were then dehydrated through ascending grades of alcohol, cleared in xylene and embedded in paraffin blockes. Sections of 5 microns were cut to be stained with following stains :

1. Haematoxylin and eosin (H&E) for general histology
2. Masson's trichrome (Culling *et al*, 1985) for collagen fibers of connective tissue.
3. Periodic acid Schiff's reaction (PAS) (Culling *et al*, 1985) for mucosubstances in general. Prior diastase digestion was also applied to differentiate between glycogenic mucosubstances from non-glycogenic mucosubstances.
4. Alcian blue (AB) pH 1.0 (Culling *et al*, 1985) for sulphated mucosubstances.
5. AB pH 2.5 for acidic mucosubstances (Culling *et al*, 1985).
6. AB (pH 2.5)/PAS combination (Culling *et al*, 1985) to differentiate between neutral mucosubstances (magenta red color) and acidic mucosubstances (blue color).

RESULTS AND DISCUSSION

Histological findings

The Weber's glands of rabbit occupy a substantial portion of the root of the tongue. These glands were consisting of a series of discrete lobules separated by well-defined connective tissue. The connective tissue was well defined after using the Masson's trichrome stain (Fig. 1). The glands lacks a separate capsule,usually the connective tissue of the lamina propria of the lingual mucosa sends septa which divide the glandular tissue into lobules (Fig. 2). The connective tissue septa were merged with the epimysium of the underlying muscle (Fig. 3). Ganglionic cells were seen in the connective tissue of the glands (Fig. 4).

The glands appear as classical tubuloacinar mixed glands, with both mucous cells (the predominant cell type) and serous cells (Fig. 5).

The mucous cells were arranged in the form of tubules. Their mucous cells have flattened basally located nuclei and pale appearance cytoplasm in H&E and Masson's trichrome stains. Some of the mucous tubules were capped by serous demilunes (Fig. 6). A group of the mucous tubules were seen departed from the main mass of the gland and lodged themselves as disarrayed tubules in the lamina propria of the oral lingual mucosa (Fig. 7).

The serous cells were identified by the characteristic morphology of their acidophilic cytoplasm with rounded nuclei (Fig. 8). The apical parts of their cytoplasm were loaded with secretory granules. The serous cells could be seen in two forms: they were either serous demilunes capping the outnumbered mucous tubules or as discrete acini embedded in between the mucous tubules (Figs. 6 and 8).

The duct system started as intercalated ducts which were seen as continuation of the secretory units (Figs. 9 and 10). This part of the duct system was lined by simple cuboidal epithelium. The intercalated ducts have joined larger calibered excretory ducts that cross the epithelium of the lingual mucosa in the root of tongue (Fig. 11).

Histochemical findings

In sections stained with PAS with and without diastase have shown that mucous acini expressed negative reaction (Fig. 12). At the same times the serous cells were reacted positively. In tissue section subjected to alcian blue staining (AB), there was positive reaction in the mucous tubules at pH 2.5 (Fig. 13), but negative reaction at pH 1.0.

With AB (pH 2.5)/PAS combination, the mucous cells of the tubules were showing bluish coloration (Fig. 14), while the serous cells were displaying red granules in their cytoplasm. The walls of the duct system have no reaction with battery of stains employed in this study.

The results of the study have shown that Weber's glands of the rabbits were different from the purely mucous glands of human being (Avery, 2002). The mixed nature of glands in rabbit was similar to that of rat (Zimermman, 1927; Nagato *et al*, 1997) and oposumms (Okada *et al*, 2013). In the rat the serous cells were bona fide of these glands (Nagato *et al*, 1997) present only in forms of serous demilunes and sometimes bordering on the tubule lumen. Separate serous acini in the rat were not seen (Nagato *et al*, 1997), as in the Weber's glands of the present study. The presence of serous cells, as serous demilunes or as separate acini, could be an extension of neighboring von Ebner's glands.

The histochemical stains of the present study have demonstrated that the nature of mucous substances present in the mucous cells of Weber's glands in rabbit suggested the presence of acidic only (positive at pH 2.5), but negative at pH 1.0. Neutral mucous substances have not been displayed due the negative staining with PAS stain. The absence of reaction after PAS stain in the mucous cells of Weber's glands was similar to the same reaction seen in the mucous cells of submandibular (Hagelqvist *et al*, 1991) and vonEbner's glands (Yasear *et al*, 2004) of the same species. However, we have demonstrated the presence of neutral mucosubstances in the serous cells of the rabbit Weber's gland. Similar reaction were seen in the serous cells of rabbit's von Ebner's glands (Yasear *et al*, 2004); submandibular gland (Hagelqvist *et al*, 1991). The mucosubstances content of Weber's glands in rabbit bear resemblance to the Weber's glands in lesser bushbaby (Smith and Pinkstaff, 1982). The presence of neutral mucous substances in the serous cells of rabbit's Weber's glands contradict the previous findings by Nogueira and Carvalho (1973), who reported an absence of such substances in these glands. The presence of serous demilunes capping the mucous tubules in the Weber's glands of the present work was comparable to the same arrangement seen in the mixed major salivary glands (Janqueira and Carneiro, 2005).

The absence of striated ducts has indicated the initial saliva produced in rabbit's Weber's glands secretory units probably reaches the oral cavity without the modification carried out by the striated ducts of other major salivary glands (Nogieria and Carvalho, 1973).

The main function of mucous produced by Weber's glands put them as part of the mucous salivary ring seen in other mammals, which includes the glosso-palatine

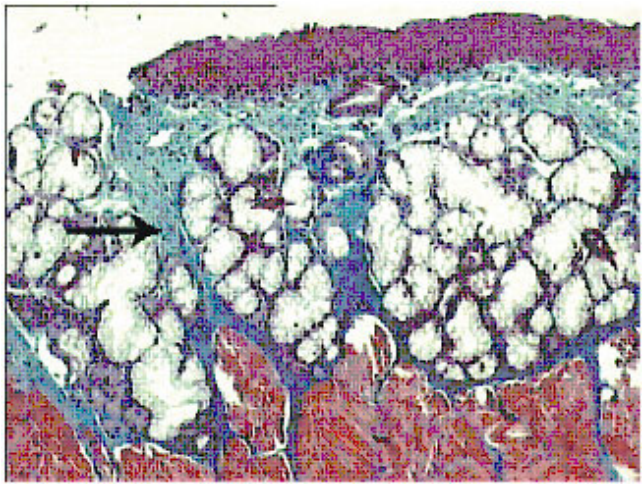

Fig. 1 : Showing the connective tissue collagen fibers (arrow) surrounding the lobules of the Weber's glands. The fibers are continuous with the epimysium of the underlying muscle. Masson's trichrome stain. X 220.

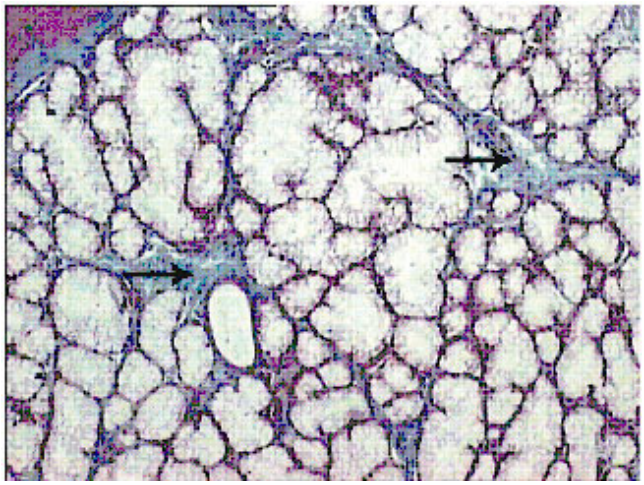

Fig. 2 : The connective tissue collagen fibers (arrows) separate the glands into lobules. Masson's trichrome stain. X 180.

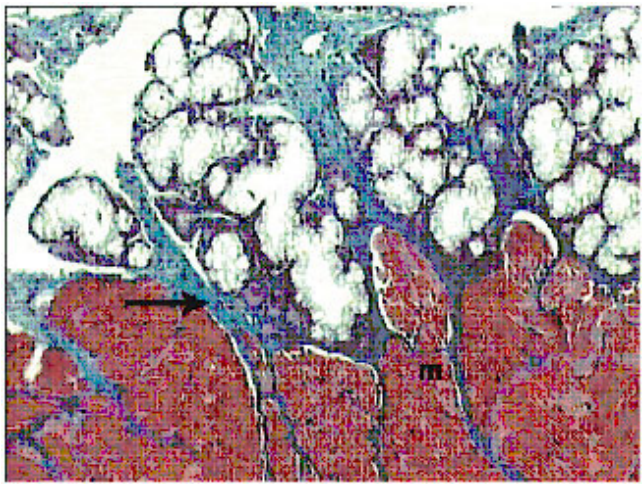

Fig. 3 : The connective tissue fibers of the glands (arrow) are merging with the epimysium of the muscle (m). Masson's trichrome stain. X 180.

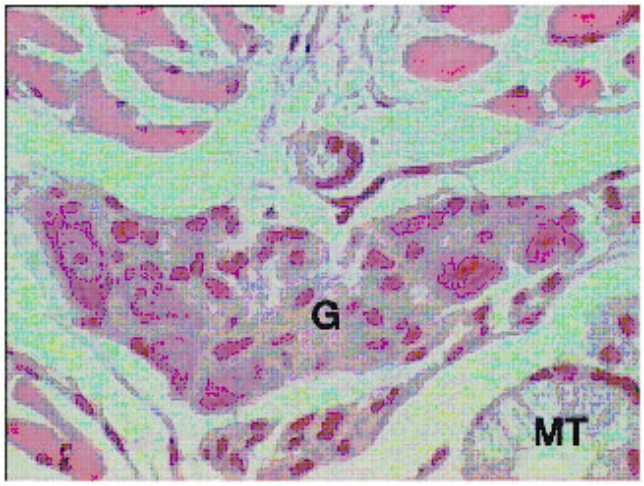

Fig. 4 : Terminal parasympathetic ganglion (G) lodged itself between the lobules of the gland (MT). Haematoxylin and eosin stain. X 400.

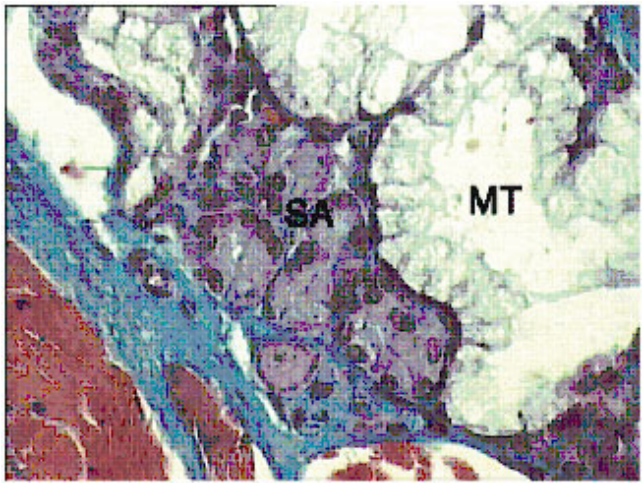

Fig. 5 : Discrete serous acini (SA) in between mucous tubules (MT). Masson's trichrome stain. X 220.

glands and palatine glands (Rival *et al*, 1999; Avery, 2002). The mucous provides a slippery substrate for easy swallowing of dry food and helps to facilitate tongue movements (Berkovitz *et al*, 2003).

A possible function for serous secretion from Weber's glands is in taste. There are large numbers of taste buds distributed in epithelial lining of the soft palate, glossopalatine folds and laryngeal surface of epiglottis (Janqueira Carneiro, 2005). We postulate that in the rabbit, the serous component of Weber's glands might fulfill this taste related role (Dawes *et al*, 2015).

REFERENCES

Avery J K (2002) *Essential of oral histology and embryology*. **2**nd ed., ,182-193 Mosby.

Berkovitz B K B, Holland G and Moxham B J (2003) Oral Anatomy, embryo. and histol., **3**rd ed. , **2002**, 256-268. Mosby Edinburgh.

Culling C F A, Allison R T and Barr P J (1985) *Cellular pathology technique*. **4**th ed.;pp:221-261; Butterworth &Co. Publishing Ltd.

Dawes A C, Pedersen A M L and Villa A (2015) The functions of human saliva: A review sponsored by the World Workshop on Oral Medicine VI. *Arch. of Oral Biol*. **60**, 863 – 874.

Enni Kaltiainen E, Wikstén J and Aaltonen L (2017) The presence of minor salivary glands in the peritonsillar space. *Eur. Arch. Otorhinolaryngol.* **274**(11), 3997-4001.

Hagelqvist E, Ahlner Bo H and Magnus Lind G (1991) Morphology and Histochemistry of Rabbit Submandibular Glands. *Acta Oto Laryngologica* **11**, 1-17.

Junqueira L C and Carneiro J (2005) *Basic histology : text and atlas*, 11th International ed.; pp 317-322; Lange McGraw Hill Medical publishing Division.

Nanci A (2003) Ten Cate's Oral histol. Development, structure and function. **6**th ed. pp 299-328. Mosby.

Nagato T, Ren X Z, Toh H and Tandler B (1997) Ultrastructure of Weber's glands of the root of the tongue in rat. *Anat. Rec.* **249**, 435-440.

Nogieria J C and Carvalho A D V (1973) Histochemistry of the mucins in posterior lingual salivary glands of some mammals. *Rev. Bras Pesquisas Med. Biol*. **6**, 267-274.

Okada H, Suemitsu M and Kanno T (2013) Morphological Features of the Posterior Lingual Glands in the Gray Short-Tailed Opossums (*Monodelphis domestica*). *J. of Hard Tissue Biol.* **22**(4), 489-492.

Rival A, Loffredo F, Puxeddu R and Testa Rival F (1999) A scanning and transmission electron microscope study of the human minor salivary glands. *Arch. of Oral Biol*. **44**, S27-S3.

Ren X Z (1999) Histoarchitecture, ultrastructure and postnatal differentiation of Weber's salivary glands in the rat. *J. Fukuoka Dental College* **26**(3), 141-157.

Smith R D and Pinkstaff C A (1982) Histology and mucosubstances histochemistry of lingual salivary glands of Galago sengalensis. In the lesser bushbaby (Galago) as an animal model: Selected topics; pp 220-230, Haines, D. E., ed. CRs Press Boca Ratton.

Tandler B and Riva A (1986) Salivary glands. In human oral . embryology and histology, Major I A and Fejerskov O eds. pp 243-284. Mungsgaard, Copenhagen.

Williams S P, Warwick, R Dyson M and Bannister L H (1989) *Gray's anatomy*, **37**th ed., p 1169; Churchill Livingstone, Edinburgh.

Yasear A Y, Sultan A and Gaballah K (2004) Histological and histochemical studies on the von Ebner's glands of the rabbit. *Cairo Dent. J.* **20**(1), 175-178.

Zimermman K W, Die speichldrusen der Mundhohle und Bauchspeicheldrus (1927) In: *handbuch der Mikroskopischen Anatomie des Menchen*, vol. **V**, Part 1. W. von Mollendrof, ed.; Springer-Verlage. Berlin, PP.61-244.